

## Cavernous sinus thrombophlebitis of pregnancy: management dilemma in a Malagasy patient

Avisoa Theodora FARE <sup>(1)</sup>, Patrick Maholisoa RANDRIANANDRAINA <sup>(1)\*</sup>, Ando Mathieu ANDRIAMAHENINA <sup>(2)</sup>, José Jean Christien RAJAONARISON <sup>(3)</sup>, Hery Henintsoa RANDRIANIRINA <sup>(4)</sup>, Rex Mario Jean RAZAFINDRAKOTO <sup>(5)</sup>.

(1) *Departement of ENT, PZAGa University Hospital of Mahajanga, Madagascar*

(2) *Ophthalmology department, PZAGa University Hospital of Mahajanga, Madagascar*

(3) *Departement of Gyneco-obstetrics, PZAGa University Hospital of Mahajanga, Madagascar*

(4) *Departement of Anesthesia, PZAGa University Hospital of Mahajanga, Madagascar*

(5) *Departement of ENT, University Hospital of Andohatapenaka, Antananarivo, Madagascar*

*\*Corresponding Author: Patrick Maholisoa RANDRIANANDRAINA, Departement of ENT, University Hospital of Mahajanga, Mail: [patrickrandy47@yahoo.fr](mailto:patrickrandy47@yahoo.fr), Phone: + 261340962818.*

### Abstract

*We report a case of infectious thrombophlebitis of the cavernous sinus in a pregnant woman, supported in the Malagasy medical context. It was a 15-week pregnant woman who has had a complicated form of facial acne. Paralysis of the right abducens nerve associated with a headache reinforced by a biological inflammatory syndrome made suspect a thrombophlebitis of the cavernous sinus. A hemoptysis associated limited the use of anti-thrombotic. Antibiotics by general means allowed signs to regress from the third day. The clinical and biological elements are crucial in the face of the contraindication and the unavailability of imaging examinations, which are necessary for diagnosis. Multidisciplinary follow-up is essential for a better prognosis of this complicated thrombophlebitis.*

*Keywords: Acne, Cavernous sinus, intracranial thrombosis, Pregnancies.*

### Introduction

Cerebral thrombophlebitis is a rare cause of stroke, the occurrence of which during pregnancy can be life-threatening. Physiological blood hypercoagulability during pregnancy makes them at risk for thrombophlebitis (1). Cerebral thrombophlebitis of pregnancy and postpartum represents 10 to 20% of cerebral venous thrombosis in general. They occur in 15 to 20 patients per 100,000 births, 3% of which involve the cavernous sinus (2). Cerebral venous thrombosis still has a poor prognosis with a mortality rate of 4.3% in the West and 25% in developing countries (3). Given the variability in the clinical signs, imaging exams are necessary for early diagnosis and management (1). Several factors have been linked to the occurrence of cerebral thrombophlebitis in pregnant women (3). We report a case of infectious thrombophlebitis of cavernous sinus in a pregnant woman, posing a diagnostic and therapeutic problem, managed in the Malagasy context.

## Observation

A 37-year-old pregnant woman, 15 weeks of amenorrhea, was admitted in the ENT department of the University hospital of Antananarivo - Andohatapenaka Hospital, for swelling of the left hemi face. This swelling had been progressing for a week before admission in a feverish context at 39 ° C. It started with an acne located at the level of the left nasolabial fold. This acne was manipulated and self-treated with an anti-inflammatory in local application. The general condition was altered, the patient complained of diffuse and intense postural headache. She was dyspneic, and coughed with hemoptoic sputum, with no notion of chest pain. The swelling of the left hemi face was inflammatory and diffuse, affecting the skin, the subcutaneous cellular tissue and the masseter muscle that produced a trismus. However, there was no chemosis or exophthalmos. The patient presented a limitation of the abduction-raising and the abduction-lowering of the right eye, with diplopia without reduction of the visual acuity, in favour of a paralysis of the right abducens nerve (Figure 1). She also experienced isolated paraesthesia of the left lower limb. The fundus examination was normal. There were no clinical signs of meningitis, and the thyroid gland was normal. Biology showed an inflammatory syndrome with a predominantly neutrophilic hyperleucocytosis at 17,000 / mm<sup>3</sup> and a CRP at 80 mg / l, with hypokalemia at 2.4 mmol / l. the blood sugar was normal. The dosage of D-dimers and the electrocardiogram were normal, eliminating a pulmonary embolism. The sputum examination eliminated pulmonary tuberculosis. The obstetric ultrasound found a healthy fetus and the doppler ultrasound of the vessels of the lower limbs was without abnormality. Cerebral computed tomography and chest radiography had not been done before pregnancy, and magnetic resonance imaging was not available.

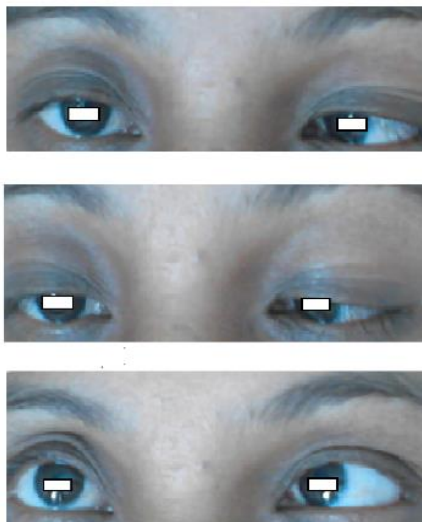


Figure 1: Strabismus translating a paralysis of the right abducens nerve

In front of these bundles of clinical and biological arguments, the diagnosis of thrombophlebitis of infectious origin of the right cavernous sinus was retained. After a multidisciplinary consultation meeting (resuscitators, obstetricians, ophthalmologists), initial antibiotic therapy was instituted with fusidic acid in local application, amoxicillin-clavulanic acid by the parenteral way, at a dose of 1 g every 6 hours for 10 days, combined with

methylprednisolone at 60 mg / day for three days then relayed orally with prednisolone for 10 days.

Hypokalemia was corrected with 1g potassium chloride injection in 500 ml of isotonic saline. The pain was managed by paracetamol 1g every 6 hours for 2 days with apyrexia on the 3rd day of treatment. However, the pulmonary signs had persisted, leading to performing a pleuro-pulmonary ultrasound which found a right pleural effusion septate. The pleural puncture was white.

On the tenth day of treatment, an overall improvement was observed with apyrexia, headache attenuation, regression of the facial swelling, trismus, dyspnea and paresthesia of the lower limb. Hemoptysis has dried up. Antibiotic therapy was replaced by oral amoxicillin-clavulanic acid. The biological check-up was normal. However, paralysis of the right abducens nerve persisted and the obstetric ultrasound showed oligoamnios. The patient was authorized to return to her home on the 15th day with regular obstetric and ENT monitoring. After three months, in the 22nd week of amenorrhea, there was a recovery of the oculomotricity after orthoptic sessions (Figure 2). The pregnancy proceeded without anomalies. The patient gave birth at term by vaginal way, without incident either during or after delivery.

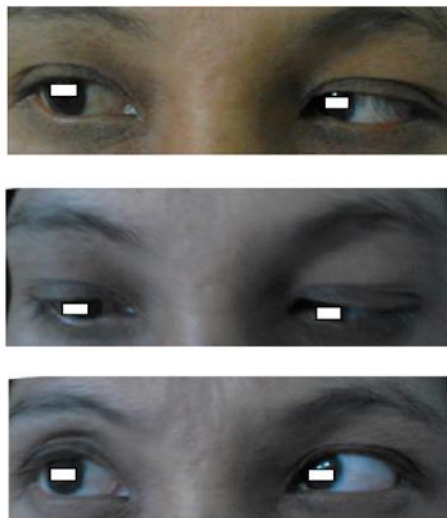


Figure 2: evolution of oculomotricity at three month rehabilitation

## Discussion

Cerebral venous thrombosis can occur at any age. Women are particularly vulnerable during pregnancy and the postpartum period (2). Cerebral venous thrombosis in pregnant women represents 10 to 20% of cases (2) with a peak incidence in the third decade (4) as in our patient.

The aetiologies of cerebral venous thrombosis are multiple, they can be of inflammatory or septic origin (5) (6). The septic causes are most often linked to locoregional infections of the face, ENT or stomatological spheres (5). The cavernous sinus thrombophlebitis described in our patient was linked to a skin infection of the face. The responsible germs isolated from

blood cultures are *Staphylococcus aureus* (65% of cases), pneumococci and gram-negative bacilli (7) (5). However, these cultures are only contributory in 20% of cases (7).

In addition to hypercoagulability in the blood during pregnancy (4), the absence of an anti-reflux valve in the drainage veins of the face allows the retrograde spread of bacteria to the cavernous sinus. For example, manipulation of an infected focus on the face can trigger bacterial spread from the pterygoid sinus which drains to the cavernous sinus (7). The presence of trismus in our patient signified the inflammation of the infra-temporal compartment drained by these pterygoid veins. In addition, the other physiological modifications of the pregnancy (cardiovascular, respiratory and immune) can influence the evolution of the pathology (1) which can explain the pulmonary dissemination of the infection in our patient.

The clinical picture of cerebral thrombophlebitis is misleading. The diagnosis is evoked in front of the variable combination of intracranial hypertension, focal neurological deficit, seizures and a picture of cavernous sinus thrombophlebitis (8). The acute form is made up in 95% of cases by the triad: chemosis, ptosis and painful ophthalmoplegia. It can be associated in 80% of cases with headache that is early, constant, retro orbital or simulating facial neuralgia (8). Our patient presented a clinical form of thrombosis of the cavernous sinus associating paralysis of the Abducens nerve with headaches, without chemosis and whose main factor of occurrence was the manipulation of the infectious entrance door. Involvement of the left cavernous sinus has been frequently reported by several authors with no obvious causes proposed (7) (6) (9) (10). This left localization was also noticed in our patient. However, the infectious portal was contralateral to the affected cavernous sinus. This contralateral localization of infectious thrombophlebitis was also reported by some authors (7) (11). This false sign of localization could be attributed to the long intracranial path of the abducens nerve, making it particularly vulnerable during a rise in intra cranial pressure. This intracranial hypertension results in the appearance of a headache, also found in our patient.

Cerebral CT is the first-line unscrambling examination for the diagnosis of thrombophlebitis of the cavernous sinus. It shows a convex and bulging aspect of the lateral wall of the sinus (8). When available, MRI associated with venous angio-MRI is the benchmark examination for early diagnosis, but also for assessing the spread of infectious lesions (8). Faced with the contraindication of CT in pregnant women and the unavailability of MRI, the diagnosis, in our case, was only based on clinical and biological elements and on the results of antibiotic therapy. Treatment is based on early antibiotics, parenteral at first, prolonged and broad spectrum pending the results of bacteriological examination, in search of resistant methicillin staphylococci. However, the antibiogram can return negative (7) (8).

The initiation of an early anticoagulant treatment would improve the prognosis of this pathology (1) (8) (10). Anti-thrombotic treatment allows the occluded venous sinus to be rehabilitated in order to reduce oculomotor sequelae. The indication is discussed because of the risk of bleeding from the treatment (12) and the role of the thrombus in curbing the extension of thrombophlebitis (8). It was not undertaken in our patient before the associated hemoptysis. On the other hand, corticosteroid therapy was effective, for the functional recovery of the paralyzed cranial nerve.

## Conclusion

Cavernous sinus thrombophlebitis in pregnant women is a multidisciplinary therapeutic emergency. Physiological changes during pregnancy make it a factor of occurrence. The limited use of imaging and antithrombotic treatment in view of the clinical form and the local context, limited management. Clinical and biological arguments thus find their importance in therapeutic decision-making, whose early initiation conditions healing. Avoiding the manipulation of acne and infectious pathologies of the face helps to avoid the occurrence of this serious complication.

## References

1. Elhassani M, Habib A, Kouach J, Sekkach Y, Bakkali H, Jira M, Elqatni M, Abouzahir A, Ghafir D, Moussaoui D, Dehayni M. *Thrombophlébite cérébrale inhabituelle du post-partum. Pan afr med J.* 2014;18:318. <https://www.ncbi.nlm.nih.gov/pmc/articles/PMC4250019/>
2. Kouach J, Mounach J, Moussaoui D, Belyamani L, Dehayni M. *Mutisme akinétique révélant une thrombose veineuse cérébrale du post-partum. Ann Fr Anesth Réanim.* 2010;29:165-9.
3. Ferro J, Canhao P, Stam J, Bousser M, Barinagarrementeria F. *Prognosis of cerebral Vein and dural sinus thrombosis: results of the International Study on Cerebral Vein and Dural Sinus Thrombosis (ISCVT). Stroke.* 2004;35:664-70. <https://pubmed.ncbi.nlm.nih.gov/14976332/>
4. Fischer U, Nedeltchev K, Gralla J, Brekenfeld C, Arnold M. *Thrombose veineuse cérébrale: mise à jour. Forum Med Suisse.* 2008;8(41):766-72.
5. Khatri I, Wasay M. *Septic cerebral venous sinus thrombosis. J Neurol Sci.* 2016;362:221-7. <https://pubmed.ncbi.nlm.nih.gov/26944152/>
6. Moalla K S, Farhat N, Emma T, Bouchhima I, Dammak M, Mhini C. *Lymphome malin non hodgkinien du sinus caverneux. Rev Neurologique.* 2016;172(Suppl1):S23-S39.
7. Prabhu S, Jain S, Singh V. *Cavernous Sinus Thrombophlebitis (Sans Thrombosis) Secondary to Odontogenic Fascial Space Infection: An Uncommon Complication with Unusual Presentation. J Maxillofac Oral Surg.* 2015;14(Suppl 1):S168-S72. <https://pubmed.ncbi.nlm.nih.gov/25838693/>
8. Crassard I, Ameri A, Rougemont D, Bousser M. *Thromboses veineuses cérébrales. Encycl Med Chir-Neurologie.* 2012;9(3):1-14.
9. Xia P, Yang J. *Septic cavernous sinus thrombosis caused by tuberculosis infection . Case report. BMJ.* 2014:206-9. <https://www.ncbi.nlm.nih.gov/pmc/articles/PMC4248139/>
10. Mansare M, Atsa Kouda D, Diallo I, Ntenga P, Boubacar S, Gams M, et al. *Thrombose du sinus caverneux: un cas unique révélant une tuberculose multifocale et revue de la littérature. African Journal of Neurological Sciences.* 2017;36(2):33-42. <https://www.ajol.info/index.php/ajns/article/view/176387>

11. Larner AJ. *False localising signs. J Neurol Neurosurg Psychiatry.* 2003;74(4):415-8.  
<https://pubmed.ncbi.nlm.nih.gov/12640051/>
12. Rakotoarisoa AHN, Riel AM, Ramarozatovo NP, Tovone XG, Rakoto F, Rakotovao FJ. *Thrombophlébite du sinus caverneux, complication d'orgelet. Revue d'Anesthésie-Réanimation et de Médecine d'Urgence.* 2011;3(2):14-7.