

**BIOEFFICACY OF *ALLIUM SATIVUM* EXTRACT IN THE CONTROL OF  
*TRICHODINA* AND *EPISTYLIS* SPP OF *CLARIAS GARIEPINUS* IN GWAGWALADA  
TOWN FCT, ABUJA**

**\*GIMBA, U.N.**

**Department of Biological Sciences, University of Abuja, Nigeria**

**P.M.B 117, Gwagwalada Abuja, Nigeria**

**\*Corresponding Author: [usnaji@yahoo.com](mailto:usnaji@yahoo.com)**

**Tell: 08036381509**

**Abstract**

*Parasitological examination was carried out in one hundred and forty-five naturally collected Clarias gariepinus from Usuma River in Gwagwalada. It revealed skin and gill infestation with ectoparasitic protozoan Trichodina and Epistylis and monogenean Tetrahymena spp. with average 20, 15 and 25%, respectively. The average total ectoparasitic infestation in the examined catfish was 60%. The significance of herbal control measures using A. sativum as a new method to eradicate such parasites, was evaluated. A bioassay of 96 hours LC50 of A. sativum emphasized that its value was 192mg/L. The herbal control with A. sativum was safe and effective to treat the ectoparasitic protozoa Trichodina and Epistylis spp. at dose 20mg/L, but not suitable for treating the monogenean Tetrahymena spp.*

**Keywords: Bioefficacy; *Allium sativum*; Extract; Control; *Trichodina*; *Epistylis* Spp; *Clarias gariepinus* and Gwagwalada.**

**Introduction**

Parasitic infections of fish are common, often debilitating to the host, fairly simple to diagnose within broad categories, and frequently amenable to treatment. Techniques for diagnosis of fish parasites include history, behavioral observation, visual examination, skin scraping, gill and fin biopsy, fecal examination (direct or flotation of a flesh free-catch specimen or vent swab), necropsy examination with squash preparations of internal organs, and histopathology.

The African catfish, *Clarias gariepinus* is one of the most important fish species for an economically successful aquaculture. However, farmers are constraint with massive fry and fingerling mortalities, especially in culture system due to the invasion of parasites. The

protozoan *Trichodina spp.* and *Epistylis spp.* are often the dominant parasites which aggravate pathological effects on fish and increasing mortality (Toksen 2007).

In the last few years, the herbal treatments were developed for replacing the chemical used for eradication of the most harmful parasites infesting terrestrial animals. In this respect, several herbs were used in pest and parasitic control as *Allium Sativum* which contains over two hundred chemically active ingredients, has long been used for the treatment of variable diseases. It has a wide range of actions against parasites (Ottesen, *et al* 2010). In addition, Kania (2010) stated that *Allium Sativum* is the newest homeopathic treatment to be suggested. Practically, Kania (2010) succeeded to treat fish infected with *Cryptocaryon irritans* with *Allium Sativum* for ten days with changing water every three days.

### **Pathological Side Effects of Infection of Fish**

The 'normal' behaviour of an individual fish under a given situation may be explained conveniently as a result of motor responses brought about by the complex integration and neurological processing of inputs from many sensory systems. Since any or all of these factors may be damaged by parasites, altered behaviour may sometimes be coincidental to infection (Poulin, 1998) and infection-associated pathology may be an inevitable consequence ('side-effect') of being colonized or inhabited by another organism (Minchella, 1985).

### **Mechanical Damage**

Many species of parasites invade the gills of fish. They can range from microscopic tubulinea or monogenea, to macroscopic annelida and arthropoda, and all can be viewed on the gill arches or nestled between the gill filaments.

Grossly visible reactions to these parasites on the fish may be noncritical and include a mild discoloration of the gill filaments or one or two white spots. In more critical cases, the fish may display heavy eroding, massive discolorations (often paler), numerous white spots, and increased mucus secretion (Toksen 2007).

### **Physiological Damage**

Proliferation of a single type of cell can cause detrimental effects in the fish host. This same proliferation of cell types is found in human diseases such as cancer. For example, carcinogenesis, especially during the initiation and promotion stages, may include interactions between a variety of agents (infectious and chemical). Generalized cell hyperplasia or cellular proliferation, observed in carcinogenesis, is recognized as a causative factor in human liver

cancer. Cell proliferation is often caused by the presence of parasites; for example, epithelial cell proliferation is commonly found in Atlantic salmon (Kania *et al.* 2010) and mucous cell hyperplasia has been found in Atlantic halibut (Otessen *et al.* 2010).

### **Reproductive Damage**

Parasites often influence their hosts through the diversion of resources either directly by using up energy and nutrients or indirectly by increasing the activity of the immune system (Candolin and Voigt 2001). Parasites may also change the behavior and food intake of the host (Candolin and Voigt 2001).

### **Methods**

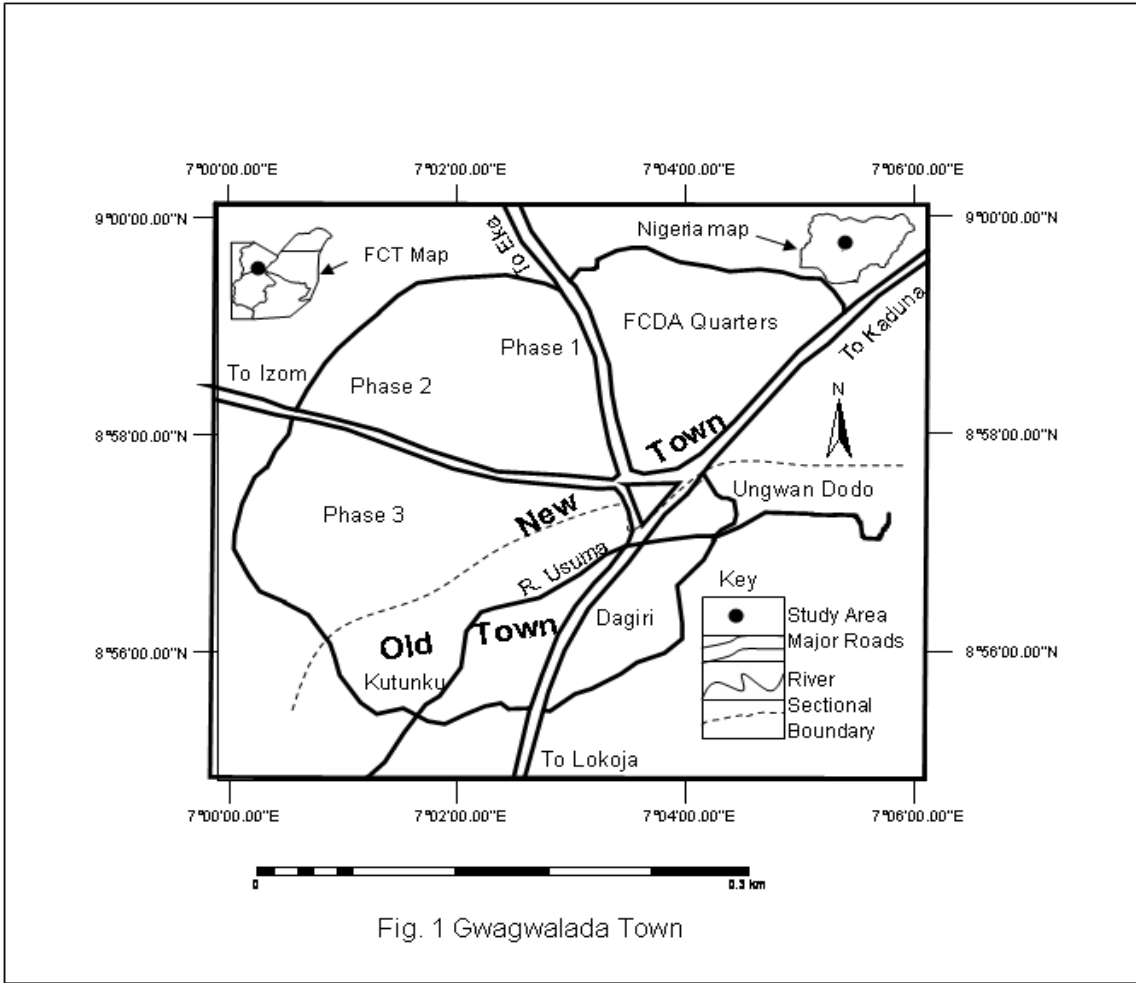
#### ***Study Area***

Gwagwalada Area Council is located about 55km away from Federal Capital City [FCT], Abuja. It lies on latitude 8°.55' and 9°.00'North and longitude 7°.00' and 7°.05'East (Ishaya, 2013). The area covers a total of 65sq kilometer located at center of very fertile area with abundance of grasses (Ishaya, 2013).

This study area falls into the guinea savanna vegetation zone of the country which is the broadest of all the vegetation types, constituting about 50% of the land area of Nigeria.

There are two seasons within this vegetational zone, dry season that lasts between four to seven months and a rainy season that lasts between four to five months. The rainfall ranges between 1016mm and 1524mm with relative humidity of between 60% and 80%. The temperature of this area is highly influenced by the Niger-Benue trough where heat is trapped. The highest diurnal temperature ranges between 27°C and 37°C in the months of November-April (dry season).

The rainy season comes between the months of April to October with temperature range of 23°C and 36°C. It is pertinent to observe that, this area has a higher temperature than any other Area Council in the Federal Capital Territory throughout the year (Ishaya, 2013).



**Figure 1:** Map of Gwagwalada Area Council, FCT-Abuja showing the Study Site.  
**Source:** Ideal Cartographic Services, Bwari-Abuja [2002].

**Allium Sativum:**

It was obtained through hydrodistillation method. *A. sativum* is belonging to the *Alliaceae* plant family. *A. sativum* contains several chemical components as outlined by Murray (1995): starch (50%), protein (9%), lipids (including glycerides, phosphatidic acid, lecithins, and fatty acids, 6-8%), protease (2.26%) and volatile oils. In addition, it contains vitamins A and B3 (niacin)

**Allium Sativum lethal concentration-50 (LC50):**

A total number of 100 fish were divided into ten groups. The fish were exposed to different concentrations of *A. sativum* (Table 2), kept under observation for 96 hours and numbers of dead fish were recorded. The results were statistically analyzed according to Moravec, *et al*, (2014) by this equation:

$$LC50 = \text{Largest dose} - \frac{\sum AXB}{N}$$

Where A is the mean of dead fish between two successive doses.

B is dose differences between two successive doses.

N is the total number of fish.

**Efficacy of *A. sativum* bath on the ectoparasites infesting *C. gariepinus*:**

A total of 45 alive naturally infested *C. gariepinus* were divided in three groups of 15 fish each in a volume of water (100x 40x 15 cm, 60 liters) with good aerated conditions. The safe level of *A. sativum* applied to infested fish was the 10 times lower than the value of *A. sativum* 96 hours LC50 (Lafferty 2008). It was approximately 20 mg/L. The fish in the first group was exposed to 10 mg/L while the second group was exposed to 20 mg/L of *A. sativum* extract and the third group was considered a control.

**Parasitological Examination of fish Parasites**

A total of 145 freshwater *Clarias gariepinus* ranged from 200-250 g body weight were collected alive from River Usuma and transported immediately to the lab in large plastic bags partially filled with water and containing air according to (Vickery and Poulin, 1998). The fish were examined for gross clinical signs and pathological lesion. The necropsy technique of parasitological examination of skin, fins and gills was carried out for the presence of external parasites with recording the average and intensity of the isolated parasites from 145 catfish, the other 45 catfish were kept for applying the treatment. The recovered protozoa and monogenea were fixed, preserved and stained according to Ottesen (2007), Vickery and Poulin (1998).



**Figure 1: Image of *Clarias gariepinus***



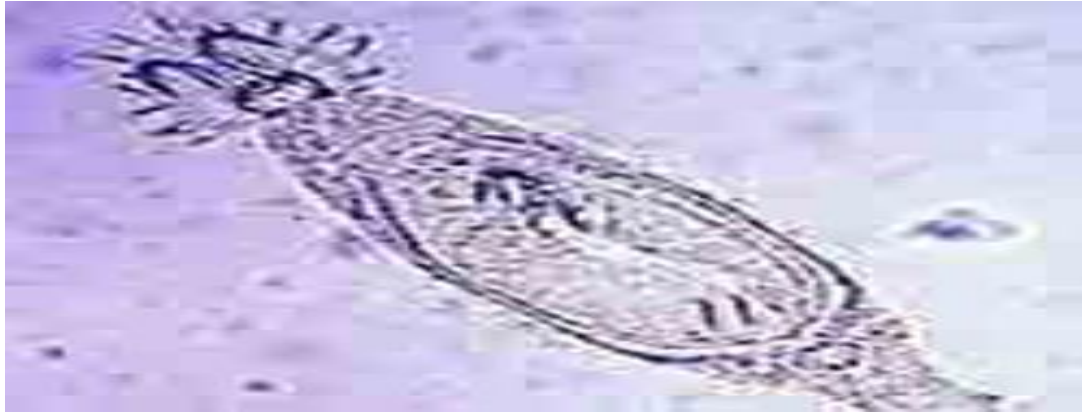

Figure 2: Image of *Trichodina spp*

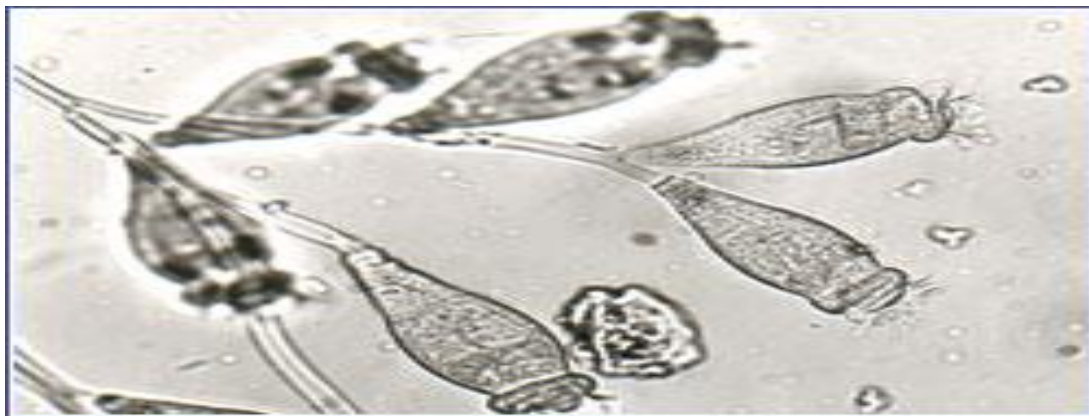

Figure 3: Image of *Epistylis spp*

**Fish Parasites Examination Procedure**

*Gill*

In the laboratory, the operculum was removed to expose the gills. A section of the first gill lamellae after the operculum on the left side was cut using dissecting scissors. The rest of the lamellae and the gill arch were discarded. The specimen was thinly spread on a slide and a drop of distilled water was added. Specimen was then covered with a cover slip and examined under the microscope with a magnification of 60X for parasites (monogeneans and *Trichodina spp*). The same procedure was repeated for all fish samples to ensure consistency in the results.

**Chemical Analysis of Water Sample**

The water samples taken from the ponds in the selected farms were analyzed for pH, dissolved oxygen, ammonia and hardness using proposed standard methods with apparatuses from Hach

Journal of Biological Science

Chemical Company (Deaton 2009). The bottles containing water samples were airtight to prevent atmospheric oxygen dissolving into it before analysis in the laboratory.

**Results**

Two protozoan and group of metazoan ectoparasites, namely *Trichodina* sp. (ciliate), monogeneans and *Tetrahymena* sp. (ciliate) were recorded from the gills and skin mucus of the Nile tilapia in the survey. The first two ectoparasites were present in almost all selected fish sites.

**Prevalence of Parasites on gills**

*Trichodina* sp. was recorded in all except one farm and monogeneans in only three. The prevalence of *Trichodina* sp. peaked at 55 % on site 1 and the lowest on peaked at 15 % on farm 2 with both sites 3 and 4 had prevalence of 10 %. No ectoparasites were observed on the gills of *Clarias gariepinus* in site 5.

**Gross macroscopic examination:**

The gross examination of infested fish with the isolated ectoparasitic protozoan, *Trichodina*, *Epistylis* and monogenean *Tetrahymena spp.* revealed pale skin and excessive mucus secretion. Skin erosion with local hemorrhagic lesions was demonstrated in some infested fish.

**Parasitological examination:**

The parasitological examination revealed single and mixed infestation of some *C. gariepinus* with the ciliated ectoparasites *Trichodina* and *Epistylis spp.* in addition to monogenean ectoparasites *Tetrahymena spp.* (Table 1).

**Table 1: Average and Intensity of Infestation with external parasities infested *Clarias gariepinus***

Parasites	No of Examined fish	Total infested fish %	Single infestation %	Mixed infestation %	Intensity of infestation No./field (10X)
<i>Trichodina</i> spp.			20		8-10
<i>Epistylis</i> spp.	100	60	15	30	15-18
<i>Tetrahymena</i> spp.			25		6-8

Based on the morphological examination of the isolated ectoparasites, they were identified as the following:

*Trichodina spp.* is isolated from skin, fins and gills of infested *C. gariepinus*. It is large with disc

Journal of Biological Science

shaped body. The adhesive disc is saucer shaped. The parasite is provided with several rows of cilia at the circular periphery and the inner circle of toothed denticles. The macronucleus is horse shoe-shaped and micronucleus is small and difficult to be seen in some specimens.

*Epistylis spp.* is isolated from skin and gills of infested catfish. It is a sessile contractile ciliate. Stalk is long and non contractile. Often forms a branched colony. The distal end of the organism is surrounded by rapidly moving cilia which appear as a blur. The monogenetic *Gyrodactylus* is detected in gills and skin of infested *C. gariepinus*. It is flat worm with one pair of projection at its anterior pole. It can be distinguished from other monogeneans by the absence of eye spots and the occurrence of the embryos in the mid-region of the bodyend has the organ of fixation, which is guarded with a number of marginal hooklets and a central one pair of hooks.

**A. sativum lethal concentration-50 (LC50):**

The result of LC50 of *A. sativum* for *C. gariepinus* after 96 hours appeared to be 192 mg/L (Table 2).

**Table 2:** Conducting of *A. sativum* LC50 for *Clarias gariepinus* after 96 hours.

Exposure Dose (mg/L)	Fish Numbers/ groups	No. of dead fish	A	B	AXB
20		0	0	0	0
40		0	0		0
60		1	0.5		10.0
80		2	1.5		30.0
100	10	3	2.5	20	50.0
120		5	4		80.0
140		7	6		120
160		8	7.5		150
180		9	8.5		170
200		10	9.5		190
Σ	100				800

LC50 = 192 mg/L



Journal of Biological Science

(A) is the mean of dead fish between two successive doses.  
 (B) is dose differences between two successive doses.

**Efficacy of *A. sativum* bath on the ectoparasites infesting *C. gariepinus*:**

The results of *A. sativum* efficacy on the infested *C. gariepinus* with mixed infestation of *Trichodina*, *Epistylis* and *Tetrahymena spp.* indicated that long exposure of infested fish for three days (long bath) to *A. sativum* at concentration 10 mg/L was insufficient to eradicate the protozoa and monogenea while *A. sativum* concentration of 20 mg/L was sufficient to eradicate the protozoa (*Trichodina* and *Epistylis spp.*) but cannot eradicate the monogenean *Tetrahymena spp.* (Table 3). Overdose of *A. sativum* caused ulceration and erosion in the skin and fins of catfish.

**Table 3:** Efficacy of *A. sativum* bath on ectoparasites infesting *C. gariepinus*.

Fish groups	<i>A. sativum</i> doses	Period of treatment/day	<i>Trichodina, spp.</i> 8/ field(10X)	<i>Epistylis, spp.</i> 18 field(10X)	<i>Tetrahymena, spp.</i> /field(10X)
1 <sup>st</sup> group (15)	10	1	8	18	6
		2	6	10	5
		3	4	5	4
2 <sup>nd</sup> group (15)	20	1	5	6	6
		2	3	2	4
		3	7	-	3
3 <sup>rd</sup> group (15)	none-treated	1	8	18	6
		2	11	18	6
		3	13	20	8

**Discussion**

All *ectoparasites* appear to be an important pathological stressor affecting fish populations in the water stratum. In the present study, the gross clinical appearance of infested *C. gariepinus* with ectoparasitic protozoa (*Trichodina* and *Epistylis spp.*) and the monogenean *Tetrahymena spp.* demonstrated pale skin, excessive mucus secretion and skin erosion with local ulcerative lesions (Fig. 1 a&b). These results were similar to that recorded by (Karvonen and Seppälä 2008).

In Table (1), the total average of ectoparasites was 60%. This result was lower than that of (Agnew 2007) (100% for protozoa and 76% for monogenea) in *Oreochromis niloticus* and higher than that recorded by Moravec *et al.* (2014) as (44.4%) among cultured *C. gariepinus* in Abassa. In addition, the average of the *Trichodina spp.* in the infested catfish was 20% which was lower than the finding of Hanna (2001) who recorded *Trichodina spp.* from gills of common carp. With concern to *Epistylis spp.*, its average was 15%. This result was lower than that recorded by Agnew (2007) in *Oreochromis niloticus* (25%).

In respect to the undesirable side effects of the chemical treatment of parasitic diseases and its public health hazards, the herbal treatment is taken place to relieve the harmful side effects of chemicals. So, in this study, the ginger was screened for its efficacy in treating *C. gariepinus* infested with a mixed infestation of *Trichodina*, *Epistylis* and *Tetrahymena spp.* To avoid overdosing of *A. sativum* and to determine an effective control dose for ectoparasites, a bioassay of ginger LC<sub>50</sub> after 96 hours was conducted (Table 2).

The value of 192 mg/L *A. sativum* after 96 hours appeared to be its lethal concentration 50 for the exposed fish. So, the safe *A. sativum* dose must be 19.2 mg/L which is 10 times lower than such value as recommended by US Environmental protection Agency (Moravec 2014) but in this study, the safe and effective dose of *A. sativum* for the exposed catfish was 20 mg/L which was approximately near the calculated safe dose 19.2 mg/L. The higher *A. sativum* doses than 20 mg/L caused various ulcerations and bloody erosions in the skin and fins of the treated fish.

The efficacy of herbal treatment with ginger (long bath) on ectoparasites of catfish (Table 3) determined that the suitable dose of ginger for eradication of ectoparasitic protozoa *Trichodina* and *Epistylis* was 20 mg/L for three successive days. On the other hand, neither the doses of 10 mg/L nor 20 mg/L of ginger was sufficient to treat the monogenean *Tetrahymena spp.* That dose of

*A. sativum* used as protozoacid was in agreement with Justine, *et al* (2010) who recorded that the safe level recommended by US Environmental protection Agency are 10 to 100 times lower than the value of 96 hrs LC<sub>50</sub>. The pungent principles (including the volatile oil Allicin) are the most medicinally potent. It was performed to fish by Moravec *et al* (2014).

### Conclusion

*A. sativum* has a good effect on treating ectoparasitic protozoa *Trichodina* and *Epistylis spp.* at dose 20 mg/L. It also improves the water quality for aquaculture operation with absence of undesirable side effects in comparison to other chemicals used in this trend.

### Recommendations

I recommend that further study on other species of *Clarias gariepinus* should be carried out to investigate the biotic factors that boost its immune mechanism to reduce infra-populations of ectoparasites. However, keeping up good sanitary conditions in the hatcheries and farms might also improve the water quality of ponds which might inhibit parasite populations.

### References

- Agnew W, Barnes AC (May 2007). "Streptococcus iniae: an aquatic pathogen of global veterinary significance and a challenging candidate for reliable vaccination". *Vet Microbiol* 122 (1-2): 1-15.
- Candolin, U., and H. R. Voigt. (2001). No effect of a parasite on reproduction in stickleback males: a laboratory artifact? *Parasitology* 122:457-464.
- Deaton, R. (2009). Effects of a parasitic nematode on male mate choice in a live bearing fish with a coercive mating system (western mosquitofish, *Gambusia affinis*). *Behavioral Processes* 80:1-6.
- Ishaya S. (2013) Analysis of Growing Season Rainfall and Temperature Variability in the Federal Capital Territory of Nigeria. *Nigeria Journal of Tropical Geography*. Vol. 4(2) pp 471-490. Nasarawa State University.
- Justine, J.-L., Beveridge, I., Boxshall, G. A., Bray, R. A., Moravec, F. & Whittington, I. D. (2010): An annotated list of fish parasites (Copepoda, Monogenea, Digenea, Cestoda and

Nematoda) collected from Emperors and Emperor Bream (Lethrinidae) in New Caledonia further highlights parasite biodiversity estimates on coral reef fish. *Zootaxa*, 2691, 1-40

Kania, P. W., O. Evnesen, T. B. Larsen, and K. Buchmann, (2010). Molecular and immunohistochemical studies on epidermal responses in Atlantic salmon *Salmo salar* L. induced by *Gyrodactylus salaris* Malmber, 1957. *Journal of Helminthology* 84:166-172.

Karvonen, A., and O. Seppälä. (2008). Effect of eye fluke infection on the growth of whitefish (*Coregonus lavaretus*) – An experimental approach. *Aquaculture* 279:6-10.

Lafferty, K. D. (2008). Ecosystem consequences of fish parasites. *Journal of Fish Biology* 73:2083-2093.

Minchella D.J. (1985) Host life-history variation in response to parasitism. *Parasitology* 90, 205–216.

Moravec, František; Justine, Jean-Lou (2014). "*Philometrids (Nematoda: Philometridae) in carangid and serranid fishes off New Caledonia, including three new species*". *Parasite* 21: 21. doi:10.1051/parasite/2014022. ISSN 1776-1042

Ottesen, O. H., E. J. Noga, and A. Amin. (2010). Histopathology of culture-associated skin erosions and papillary hyperplasia of Atlantic halibut, *Hippoglossus hippoglossus* (L.). *Journal of Fish Diseases* 33:489-496.

Toksen, E. (2007). *Lernanthropus kroyeri* van Benden, 1841 (Crustacea: Copepoda) infections of cultured sea bass (*Dicentrarchus labrax* L.). *Bulletin of the European Union of Fish Pathologists* 27:49-53.

Vickery and Poulin (1998) Parasitised non-choosy females do slow down the process: a reply to J. Rolff. *Behav. Ecol. Sociobiol.* 44, 75-76.