

Study of histopathologic spectrum and microbiologic correlation of sinonasal fungal rhinosinusitis.

Dr Tanushri Mukherjee Oncopathologist, Dr Rajat Dutta Surgeon,

Dr Ravi Roy ENT Spl, Dr Nalin Singh Resident pathology.

Abstract

Fungal Rhinosinusitis is common in sinonasal tract and it can be non-invasive and invasive. Non-invasive when there is either a fungus ball or an allergic fungal rhinosinusitis. Invasive forms present clinically as acute, chronic and chronic granulomatous rhinosinusitis. 100 patients with fungal sinusitis and rhinitis were studied in this study, 88% were non-invasive (46% had allergic fungal rhinosinusitis, 40% Fungus ball, and 2% combined allergic fungal rhinosinusitis, 12% were invasive. Histopathology and fungal isolates confirmed aspergillus sp in 54% of cases, Candida sp in 34% cases however 10% isolates were Penicillium and fusarium and Mucor was found in two percent of cases of invasive mucormycosis.

Introduction

Fungi are eukaryotes and are strictly aerobic or facultative anaerobic. Most fungus causing acute (Mycoses) and human infections are free living in nature Fungal rhinosinusitis presents in varied way causing diverse histopathological changes causing mycoses in acute forms when they are seen actually in the tissue and cause necrosis and destruction of sinonasal submucosal tissue. Non-invasive forms include fungal ball (FB (a ball of fungus without significant surrounding sinonasal inflammatory reaction) and allergic fungal rhinosinusitis is characterized by the presence of allergic mucin and these are treated by surgical intervention and/or medical therapy. Invasive fungal infection is seen in immunocompromised and HIV patients with the presence of fungal hyphae with fatal symptoms due to massive tissue damage and blood vessel invasion and requires immediate

medications urgent surgical interventions like debridement to save the life of the patients. Invasive chronic fungal infection could be chronic and chronic granulomatous and requires medical therapy and surgical intervention. In our study, we analysed the type of fungus seen in histopathology correlating with the clinical symptoms, and including its pathology and microbiology with relevance in the sinonasal tract.

Materials and Methods: -

This is a retrospective observational study. The surgical pathology reports and histologic slides were reviewed. The Haematoxylin eosin slides as well as PAS and Grocott stained slides were evaluated for the type of fungus based on the morphology and branching patterns. Methamine silver stain was also done. Results of fungal cultures were correlated with the histopathologic findings.

Results

One hundred patients were identified from the archives of the department of pathology and microbiology and the tissue blocks were recut and stain for the retrospective study. Overall the mean patient age was 60 (range 18–90) with a male to female ratio of 1.5: 1. 88% had non-invasive disease with 40% having fungal ball (Fig 1), 46.0% allergic fungal rhinosinusitis, 2% combined fungal ball and rhinosinusitis and 12% had invasive disease. In forty patients fungal ball was identified histologically in H&E stains, with loads of fungal hyphal and yeast forms with no tissue invasion [3, 4]. In 46 patients allergic fungal rhinosinusitis was seen with pink staining lamellated mucin with eosinophilic debris and fungal hyphae or mucin without fungi but with culture growing fungus[5–7]. *Aspergillus* sp. with acute angled branching septate fungal hyphae was seen in 54% of cases of non-invasive fungal infection and in 34% sections and fungal isolates grew *Candida* sp which were confirmed to be *Candida albicans*. Twelve patients were classified as having Acute invasive fungal rhinosinusitis. In these 12 cases six were immunocompromised on some

therapy and were kidney recipients, two were HIV positive, two were chronic alcoholic and two patients were diabetic as per the clinical notes. Hyphal forms with acute angled septate branching *Aspergillus* sp. was seen in the sections in 09 cases and broad hyphae of mucor (Fig 2&3) with 90-degree branching seen in three cases with evidence of invasiveness and blood vessel invasion. Non invasive and allergic fungal sinusitis treated by surgery and systemic steroids and intra nasal steroids. Invasive fungal infection in our cases were treated with amphotericin B (1-1.5 mg/kg/d) after surgical treatment.

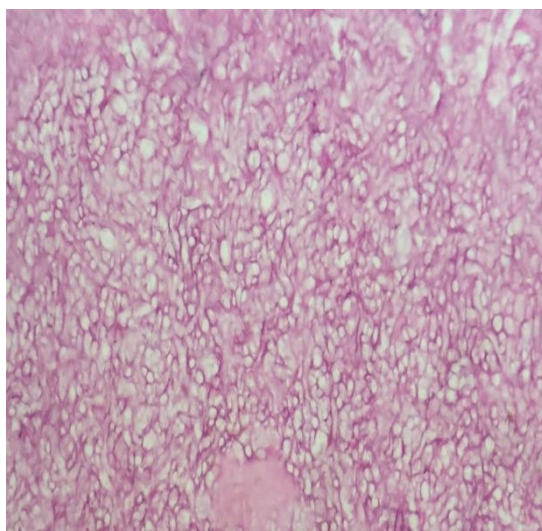


Figure 1: Photomicrograph showing aspergillus fungal ball with hyphae with 45-degree branching

Figure 2: Photomicrograph showing invasive mucormycosis with broad based hyphae of mucor with 90-degree branching.

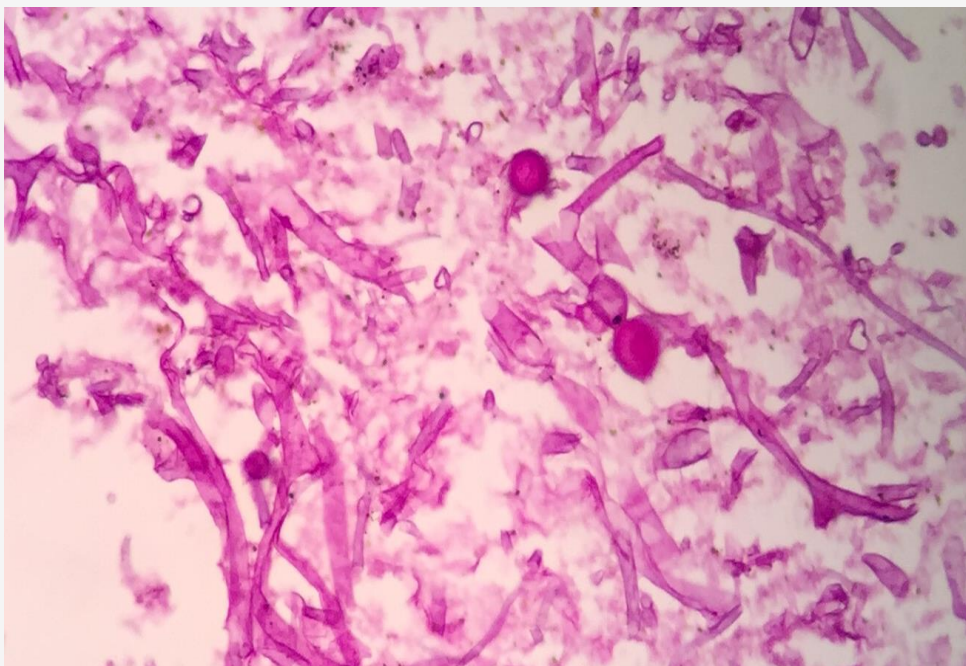
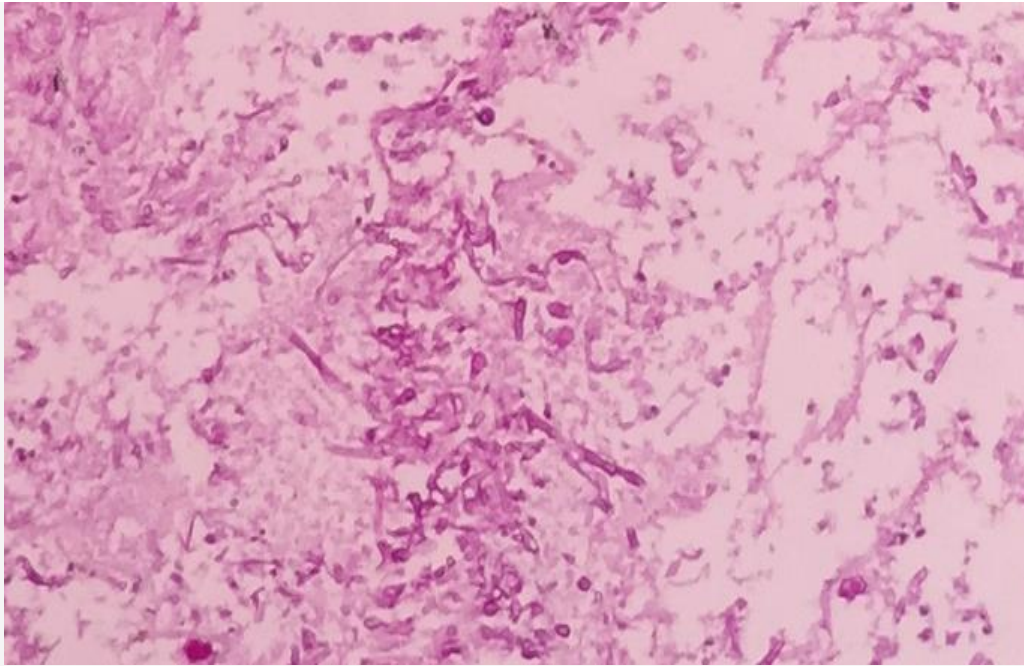


Figure 2: Photomicrograph showing PAS stain with PAS positive pink coloured broad based hyphae of mucor with 90-degree branching.

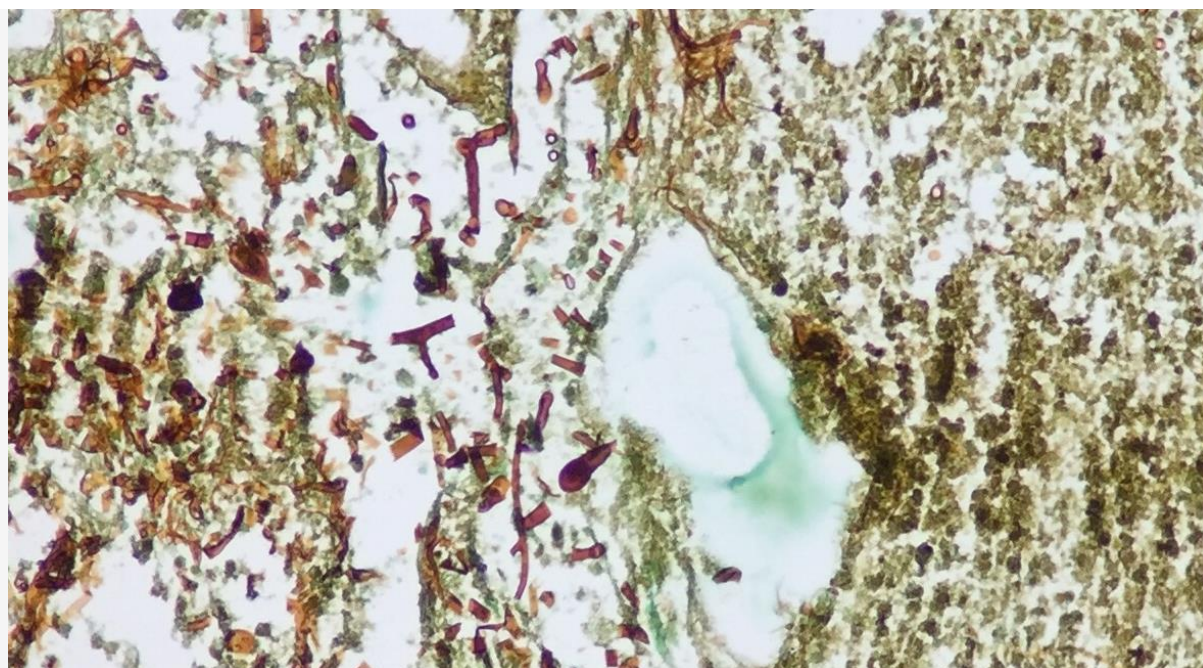


Figure 2: Photomicrograph showing Grocott stain with mucor with 90 degree branching

Discussion

- There are varied clinic-pathological presentation of fungal rhinosinusitis ranging from acute aggressive to chronic form of involvement[1–3]. This variation in clinicopathologic and microbiologic presentation may be due to varied climatic and environmental influences.

In our retrospective study, the overall mean patient age was 60 (range 18–90) with a male to female ratio of 1.5: 1. 88% had non-invasive disease with 40% having fungal ball, 46.0% allergic fungal rhinosinusitis, 2% combined fungal ball and rhinosinusitis and 12% had invasive disease. In forty patients fungal ball was identified histologically in H&E stains, with loads of fungal hyphal and yeast forms with no tissue invasion [3, 4]. In 46 patients allergic fungal rhinosinusitis was seen with pink staining lamellated mucin with eosinophilic debris and fungal hyphae or mucin without fungi but with culture growing fungus [5–7]. In Study by Granville et al. showed in 23% patients aspergillus fungal ball,

and 2.1% cases acute rhinosinusitis and 3.1% with chronic rhinosinusitis [8]. Study by Taxy et al showed 80% of non-invasive fungal rhinosinusitis cases and 8% invasive cases. [9]. Indian data showed in study by Das et al. non-invasive rhinosinusitis in 60% cases and invasive in 36% of patients. [10]. Michael et al. observed a prevalence of 63% non-invasive and 24% invasive fungal rhinosinusitis (11). Study by Panda et al. showed 60% non-invasive cases [12]. Challa et al. studied non-invasive (25%) and invasive (75%) (12)

In our study the most common fungus was *Aspergillus* sp. with acute angled branching septate fungal hyphae was seen in 54% of cases of non-invasive fungal infection and in 34% sections and fungal isolates grew *Candida* sp which were confirmed to be *Candida albicans*. Twelve patients were classified as having Acute invasive fungal rhinosinusitis. In these twelve cases, six were immunocompromised on some therapy and were kidney recipients, two were HIV positive, two were chronic alcoholic and two patients were diabetic as per the clinical notes. Hyphal forms with acute angled septate branching *Aspergillus* sp. was seen in the sections in 09 cases and broad hyphae of mucor with 90-degree branching seen in three cases with evidence of invasiveness and blood vessel invasion. Study by Granville et al., showed 70% of non-invasive cases grew dematiaceous fungi[8]. Study by Schubert and Goetz showed that *Bipolaris* sp. In 70 % cases and only 9% due to *Aspergillus* sp. (6-7).

Conclusion

Sinonasal tract fungal infections have great variation in clinicopathologic and microbiologic presentation and which is due to varied climatic and environmental influences and persistence of fungal infections in an area and that should be correlated and is required for immediate medical and surgical intervention for life saving measures.

References

1. A. Chakrabarti, A. Das, and N. K. Panda, "Controversies surrounding the categorization of fungal sinusitis," *Medical Mycology*, vol. 47, supplement 1, pp. S299–S308, 2009.
2. A. Chakrabarti, D. W. Denning, B. J. Ferguson et al., "Fungal rhinosinusitis: a categorization and definitional schema addressing current controversies," *Laryngoscope*, vol. 119, no. 9, pp. 1809–1818, 2009.
3. R. D. DeShazo, K. Chapin, and R. E. Swain, "Fungal sinusitis," *New England Journal of Medicine*, vol. 337, no. 4, pp. 254–259, 1997.
4. R. D. DeShazo, M. O'Brien, K. Chapin et al., "Criteria for the diagnosis of sinus mycetoma," *Journal of Allergy and Clinical Immunology*, vol. 99, no. 4, pp. 475–485, 1997.
5. R. D. DeShazo and R. E. Swain, "Diagnostic criteria for allergic fungal sinusitis," *Journal of Allergy and Clinical Immunology*, vol. 96, no. 1, pp. 24–35, 1995.
6. M. S. Schubert, "Allergic fungal sinusitis," *Otolaryngologic Clinics of North America*, vol. 37, no. 2, pp. 301–326, 2004.
7. M. S. Schubert, "Allergic fungal sinusitis: pathophysiology, diagnosis and management," *Medical Mycology*, vol. 47, supplement 1, pp. S324–S330, 2009.
8. L. Granville, M. Chirala, P. Cernoch, M. Ostrowski, and L. D. Truong, "Fungal sinusitis: histologic spectrum and correlation with culture," *Human Pathology*, vol. 35, no. 4, pp. 474–481, 2004.

9. J. B. Taxy, "Paranasal fungal sinusitis: contributions of histopathology to diagnosis: a report of 60 cases and literature review," *American Journal of Surgical Pathology*, vol. 30, no. 6, pp. 713–720, 2006.
10. A. Das, A. Bal, A. Chakrabarti, N. Panda, and K. Joshi, "Spectrum of fungal rhinosinusitis; Histopathologist's perspective," *Histopathology*, vol. 54, no. 7, pp. 854–859, 2009.
11. R. Michael, J. Michael, R. Ashbee, and M. Mathews, "Mycological profile of fungal sinusitis: an audit of specimens over a 7-year period in a tertiary care hospital in Tamil Nadu," *Indian Journal of Pathology and Microbiology*, vol. 51, no. 4, pp. 493–496, 2008.
12. N. K. Panda, S. C. Sharma, A. Chakrabarti, and S. B. S. Mann, "Paranasal sinus mycoses in north India," *Mycoses*, vol. 41, no. 7-8, pp. 281–286, 1998.
13. S. Challa, S. G. Uppin, S. Hanumanthu et al., "Fungal rhinosinusitis: a clinicopathological study from South India," *European Archives of Oto-Rhino-Laryngology*, vol. 267, no. 8, pp. 1239–1245, 2010.
14. J. U. Ponikau, D. A. Sherris, E. B. Kern, et al., "The diagnosis and incidence of allergic fungal sinusitis," *Mayo Clinic Proceedings*, vol. 74, no. 9, pp. 877–884, 1999.
15. J. U. Ponikau, D. A. Sherris, A. Weaver, and H. Kita, "Treatment of chronic rhinosinusitis with intranasal amphotericin B: a randomized, placebo-controlled, double-blind pilot trial," *Journal of Allergy and Clinical Immunology*, vol. 115, no. 1, pp. 125–131, 2005.